Check for updates

Stroke

ORIGINAL CONTRIBUTION

Hypoperfusion on Early MRI Despite Successful Thrombectomy: A Prospective Imaging and Inflammatory Biomarkers Study

Adrien ter Schiphorst, MD, PhD; Pierre Seners, MD, PhD; Cyril Dargazanli, MD, PhD; Julien Labreuche, MSc; Nicola Marchi, PhD; Nicole Yuen, MSc; Soren Christensen, PhD; Francesca Rapido, MD, PhD; Marine Blaquière, MSc; Michael Mlynash, MD, MSc; Maarten G. Lansberg, MD, PhD; Jeremy J. Heit, MD, PhD; Thibaut Roux, MD; Lucas Corti, MD; Isabelle Mourand, MD; Xavier Ayrignac, MD; Emmanuelle Le Bars, PhD; Marinette Moynier, MSc; Gregory Gascou, MD; Pierre Henri Lefevre, MD; Federico Cagnazzo, MD; Thomas Checkouri, MD; François-Louis Collemiche, MD; Quentin Varnier, MD; Caroline Arquizan, MD; Jean-Marc Olivot, MD, PhD; Jean-Claude Baron, MD, ScD; Gregory W. Albers, MD; Vincent Costalat, MD, PhD

BACKGROUND: Persistent hypoperfusion despite successful endovascular treatment (EVT) for acute ischemic stroke (AIS) due to large-vessel occlusion is increasingly recognized as associated with poor outcome. It may result from residual distal macrovascular occlusion or microvascular dysfunction (no-reflow). We aimed to characterize early post-EVT hypoperfusion on magnetic resonance imaging and assessed its relationship with a panel of inflammatory biomarkers.

METHODS: We performed a single-center prospective cohort study at Montpellier Hospital (France, August 2023–November 2024). We included patients with large-vessel occlusion-related acute ischemic stroke and successful (modified Thrombolysis in Cerebral Infarction [mTICI] ≥2b) recanalization who underwent magnetic resonance imaging perfusion as early as feasible after EVT and blood sampling before, during, immediately after, and 24 hours after EVT. Hypoperfusion within the affected vascular territory was assessed using 3 complementary approaches: (1) significant macrovascular hypoperfusion (time-to-maximum >6 s) in any location; (2) wedge-shaped perfusion deficits on time-to-maximum maps, indicative of distal emboli; and (3) visual microvascular hypoperfusion within the infarct core on cerebral blood volume or flow maps (2-rater assessment). Associations between macrovascular hypoperfusion and levels of 37 inflammatory biomarkers, measured using multiplex immunoassays, were analyzed cross-sectionally at each time point, using Mann-Whitney *U* tests with false discovery rate correction.

RESULTS: Seventy-one patients were included. Median time from recanalization to magnetic resonance imaging perfusion was 45 (19–118) minutes. Time-to-maximum>6 s hypoperfusions were found in 21% of all patients; percentages decreased with better mTICI grades: 45%, 13% and 0% in mTICI 2b, 2c, and 3, respectively. Wedge-shaped hypoperfusion deficits were observed in 97% of mTICI2b, 44% of mTICI2c, and 8% mTICI3 cases. Microvascular hypoperfusion was rare (6%). Several inflammatory markers showed uncorrected associations with time-to-maximum >6 s hypoperfusion, but none survived false discovery rate correction.

CONCLUSIONS: Early perfusion deficits after EVT most often reflect residual distal emboli. Macrovascular hypoperfusion was not associated with inflammatory biomarkers. Nevertheless, our integrated imaging and biomarker strategy lays the foundation for future mechanistic and therapeutic studies targeting microvascular reperfusion failure.

GRAPHIC ABSTRACT: A graphic abstract is available for this article.

Key Words: biomarkers ■ inflammation ■ ischemia ■ perfusion ■ thrombectomy

Stroke FIRST PROOF ONLY

Downloaded from http://ahajournals.org by on February 11, 2026

Correspondence to: Adrien ter Schiphorst, MD, PhD, Neurology Department, CHU Gui de Chauliac, 80 Ave Augustin Fliche, Montpellier 34295, France. Email adrien.ter.schiphorst@gmail.com

This manuscript was sent to Irene L. Katzan, Guest Editor, for review by expert referees, editorial decision, and final disposition.
Supplemental Material is available at https://www.ahajournals.org/doi/suppl/10.1161/STROKEAHA.125.052873.
For Sources of Funding and Disclosures, see page XXX.
© 2026 American Heart Association, Inc.
Stroke is available at www.ahajournals.org/journal/str

Nonstandard Abbreviations and Acronyms

AIS	acute ischemic stroke
ASPECT	Alberta Stroke Program Early Computed Tomography Score
CBF	cerebral blood flow
CBV	cerebral blood volume
CCL	C-C motif ligand chemokine
DSA	digital subtraction angiography
DWI	diffusion-weighted imaging
ECASS-II	European Cooperative Acute Stroke Study
EVT	endovascular treatment
IL	interleukin
IQR	interquartile range
LVO	large-vessel occlusion
MISO	Multimodal Analysis of the Origin of Intracranial Thrombi
MRP	magnetic resonance perfusion imaging
mRS	modified Rankin Scale
mTICI	modified Thrombolysis in Cerebral Infarction
Tmax	time-to-maximum

In acute ischemic stroke (AIS) due to large-vessel occlusion (LVO), endovascular treatment (EVT) achieves over 80% recanalization rates and improves functional outcomes.[1] However, nearly half of recanalized patients fail to achieve functional independence,[1] a phenomenon termed futile recanalization.[2,3] Mechanisms of futile recanalization include early extensive infarct core—that is, tissue that is already irreversibly damaged at the time of reperfusion—as well as edema, hemorrhagic transformation, and no-reflow.[3] The latter, defined as impaired capillary reperfusion despite angiographic success, has gained increasing attention.[4–15]

In experimental models, no-reflow occurs early after arterial reopening and is driven by multifactorial microvascular dysfunction.[16–19] Reported mechanisms include astrocyte and endothelial swelling, pericyte contraction, leukocytes, platelets and erythrocytes aggregation, and the release of inflammatory mediators.[20–24] Regarding the latter, cytokines and adhesion molecules have been implicated in its pathogenesis in preclinical studies.[24] These findings have led to the hypothesis that inflammation may contribute to microvascular perfusion failure after EVT, potentially opening the door to targeted therapeutic interventions.[20–24] However, this has never been systematically investigated in humans.

In clinical practice, persistent hypoperfusion on post-EVT computed tomography (CT) perfusion or magnetic resonance perfusion imaging is frequently interpreted as a radiological correlate of no-reflow.[4–15] Yet this interpretation remains uncertain. First, no direct histological evidence of no-reflow has been demonstrated in human stroke to date. Second, most imaging-based studies on no-reflow have included patients with residual distal emboli,[10,12,25] which cause residual hypoperfusion on a macrovascular level.[26] Third, many studies did not exclude confounders, such as perfusion abnormalities caused by carotid stenosis, parenchymal hemorrhage, or reocclusion.[14] These limitations may explain the wide variability in the reported prevalence of postthrombectomy hypoperfusion, from 0% to 80%.[14,25]

Moreover, few studies have assessed perfusion imaging in the immediate post-EVT phase, a critical time window during which microvascular dysfunction may be most pronounced[15] and potentially reversible with adjunctive therapies.[19,24] Notably, among the few human studies with early post-EVT perfusion assessment,[12,15,25–27] none has clearly distinguished between microvascular dysfunction and residual macrovascular occlusions. Finally, no clinical study to date has examined the relationship between post-EVT hypoperfusion and inflammatory biomarkers, particularly those obtained from the ischemic territory distal to the thrombus, which may better reflect the local pathophysiological environment.[28]

To address these gaps, we conducted a prospective study combining early postthrombectomy magnetic resonance imaging (MRI) perfusion imaging and serial inflammatory biomarker analysis in patients with LVO-related AIS, including central intracranial samples collected just distal to the clot before recanalization. Our objectives were to: (1) characterize early post-EVT hypoperfusion patterns on MRI, distinguishing macrovascular from microvascular mechanisms; (2) assess their association with the degree of angiographic recanalization; and (3) evaluate the relationship between inflammatory biomarkers and early hypoperfusion. This integrative approach was designed to shed light on the pathophysiology of post-EVT hypoperfusion and to support future studies on the potential role of inflammation in microvascular reperfusion failure.

Stroke FIRST PROOF ONLY

METHODS

The data supporting the study findings are available on reasonable request.

Study Design, Population, Data Sources

This is a single-center observational study including patients from the MISO cohort (Multimodal Analysis of the Origin of Intracranial Thrombi), a prospective cohort of patients aged >18 years old with AIS due to intracranial LVO treated by EVT at the Montpellier University Hospital, without known infection at the time of EVT.[28] The primary objective of the MISO cohort was to identify biological biomarkers associated with radiological and clinical outcomes, by collecting both peripheral and intracranial

Downloaded from http://ahajournals.org by on February 11, 2026

blood samples.[28] From August 2023 to November 2024, only patients with anterior circulation LVO, successful recanalization (modified Thrombolysis in Cerebral Infarction [mTICI] score ≥2b, as assessed by the treating interventional neuroradiologist), and without significant intracranial or extracranial stenosis on digital subtraction angiography (DSA) at the procedure completion, were enrolled in MISO. The goal was to assess the relation between inflammatory biomarkers and postthrombectomy hypoperfusion. These patients systematically underwent an early postthrombectomy brain magnetic resonance perfusion imaging (MRP), typically performed within 2 hours after puncture and no later than 6 hours. A follow-up perfusion MRI at 24 hours was also obtained for most patients. Exceptions included drip-and-ship patients who were transferred back to their primary stroke center or patients placed under palliative care. Due to logistical constraints, only patients treated during daytime hours on weekdays were enrolled in MISO.

Patients from the MISO cohort were included in the present analysis if they fulfilled all the following criteria: (1) anterior circulation LVO (occlusion of the internal carotid artery or M1 and M2 portions of the middle cerebral artery); (2) mTICI recanalization 2b-3 after independent neuroradiologist reading (see below); (3) acquisition of an early postthrombectomy MRP. Exclusion criteria included (1) MRP with inadequate quality; (2) any condition that may affect early MRP interpretation, including significant (>50%) carotid or intracranial stenosis visible on final DSA run or early follow-up imaging, and vessel reocclusion or presence of parenchymal hematoma on early follow-up imaging (Figure S1).

Ethics Approval

The MISO cohort was approved by the Montpellier University Hospital (RECHMPL1880236, Comité de Protection des Personnes [CPP] No. 2019.10.04_19.07.30.36737).[28] Informed consent was obtained from all participants through a consent form. This study was approved by the ethics committee (IRB 2024-08-123). Reporting was performed according to the STROBE statement (Strengthening the Reporting of Observational Studies in Epidemiology).[29]

Imaging Acquisition and MRP Processing

Early postthrombectomy MRI was performed on a 1.5T Siemens Magnetom Sola system (Siemens Healthineers, Munich, Germany), using a standardized protocol. The protocol included sagittal 3-dimensional T1-weighted, axial DWI (diffusion-weighted imaging), axial fluid-attenuated inversion recovery, axial susceptibility-weighted imaging, 3-dimensional time-of-flight angiography, multidelay pseudo-continuous arterial spin labeling, and dynamic susceptibility contrast MRP. All 24-hour follow-up MRIs were performed using the same system and protocol. Full acquisition parameters are detailed in the Supplemental Material.

Post-EVT Recanalization Grading (Independent Neuroradiologist Reading)

Recanalization was independently assessed by an experienced neuroradiologist (C.D.), blinded to clinical and imaging data. Final DSA runs were used to assign mTICI grades.

Perfusion Analysis Methodology

All perfusion data were processed using Rapid (iSchemaView, Menlo Park, CA) to generate time-to-maximum (Tmax), mean transit time relative cerebral blood flow (CBF), and relative cerebral blood volume (CBV) maps. All maps were visually inspected by an experienced stroke neurologist (A.t.S.) to ensure segmentation quality and eliminate artifacts.

To characterize post-EVT hypoperfusion, we used 3 complementary approaches within the affected vascular territory: (1) an automated quantitative analysis based on Tmax>6 s volume; (2) a visual analysis of wedge-shaped perfusion anomalies suggestive of distal occlusions based on Tmax maps; and (3) a visual assessment of microvascular hypoperfusion within the infarct area, based on CBV and CBF maps. The same methodology was used for both the early post-EVT MRP and the 24-hour MRP. For the 24-hour imaging assessment, we excluded patients with proximal vessel reocclusion (terminal carotid, M1, and M2 segments), significant carotid or intracranial stenosis, or parenchymal hemorrhage (parenchymal hematoma 1 and parenchymal hematoma 2), which may have appeared between the early and 24-hour imaging.

Quantitative Assessment of Hypoperfusion (Tmax>6 s Maps)

Persistent hypoperfusion was defined as areas with Tmax>6 s within the vascular territory of the baseline occlusion, as in previous studies.[12,14,25]

Evaluation of Distal Occlusion-Related Hypoperfusions (Wedge-Shaped Hypoperfusions)

To distinguish macrovascular causes of hypoperfusion, that is, hypoperfusions linked to residual distal occlusions, we applied a method adapted from Mujanovic et al.[26] Early post-EVT Tmax maps were reviewed by a vascular neurologist (A.t.S.), blinded to clinical data and mTICI score, to identify patients with wedge-shaped hypoperfusion patterns ipsilateral to the infarct, suggestive of residual distal occlusions. These hypoperfused areas were then correlated with final DSA images, jointly reviewed by a neuroradiologist (C.D.) and a neurologist (A.t.S.), to determine anatomic concordance between hypoperfusion and persistent distal occlusion, and to detect potential missed occlusions in patients graded as mTICI 2c-3. Wedge-shaped hypoperfusions with concordant distal occlusions on DSA were interpreted as likely attributable to macrovascular causes,[26] and were not included in the microvascular perfusion analysis (see below).

Visual Assessment of Microvascular Hypoperfusion Within the Infarct Core

Microvascular reperfusion was visually evaluated within the infarct area on CBV and CBF maps, using a multistep protocol, adapted from a previous study,[11] aiming to isolate true microvascular perfusion deficits and reduce the influence of confounding macrovascular or hemorrhagic factors (Figures S2 through S4):

1. Preinterventional CT and MRI images, including perfusion imaging, were screened to look for pathologies that could potentially confound microvascular reperfusion grading on CBV or CBF maps (eg, prior infarct). These areas were excluded from the visual analysis (Figure S2).
2. Presence of hemorrhagic infarction (hemorrhagic infarction 1 or 2 on ECASS-II [European Cooperative Acute

Stroke FIRST PROOF ONLY

Downloaded from http://ahajournals.org by on February 11, 2026

Stroke Study] classification[30]) within the infarct was assessed using both susceptibility-weighted imaging and T2*-weighted perfusion images.

3. The infarct area was coregistered with CBV, CBF, and T2*-weighted perfusion images, using Rapid software. The infarct area was defined using the 24-hour DWI, or the early post-EVT DWI when 24-hour imaging was unavailable.
4. Perfusion was visually assessed within the infarct on the CBV and CBF maps by 2 independent readers (A.t.S., P.S.), compared with the contralateral region in the unaffected hemisphere. The infarct area was rated as hypoperfused, normoperfused, or hyperperfused. In case of an infarct presenting with both hypoperfusion and normoperfusion or hyperperfusion, hypoperfusion was retained if visually occupying roughly ≥1 of 4 of the infarct territory. Readers were asked to exclude the following areas from the analysis:
   Infarcts within wedge-shaped hypoperfused territories with proven distal occlusion on DSA (see above), where distinction between hypoperfusion due to distal occlusion or to microvascular failure was not possible (Figure S3). If the infarct was confined solely to the area of wedge-shaped hypoperfusion, patients were excluded from the microvascular hypoperfusion analysis. A similar approach was used for 24-hour perfusion assessment for patients with delayed distal occlusion at this time point (Figure S3).
   Areas with hemorrhagic infarction (hemorrhagic infarction 1 or hemorrhagic infarction 2) identified on susceptibility-weighted imaging and T2*-weighted perfusion images(see above): reperfusion status was not evaluated within and around the hemorrhage, as hemorrhagic infarctions disturb the perfusion signal and therefore preclude the accurate assessment of reperfusion (Figure S4). If the hemorrhagic infarction affected most of the infarct, patients were excluded from the microvascular hypoperfusion analysis.
5. Discrepancies between readers were resolved by consensus, and patients were classified into 2 groups: hypoperfusion versus no hypoperfusion (including normoperfusion and hyperperfusion).

Biological Data

Blood samples were collected at 4 predefined time points: (1) arterially at the time of arterial puncture for EVT, (2) distal to the clot via the microcatheter before recanalization, (3) arterially at the time of catheter removal at the end of EVT, and (4) at 24 hours via a venous blood draw. The intracranial (central) sample allowed targeted analysis of the local ischemic environment, as previously described.[28] A panel of 37 inflammatory biomarkers was quantified using multiplex immunoassays (V-Plex Neuroinflammation Panel 1 Human Kit, catalog no. K15210D; MSD). This exploratory panel was selected based on preclinical evidence implicating specific cytokines and adhesion molecules in the pathogenesis of microvascular no-reflow and on prior human studies linking several of these biomarkers to stroke outcome.[20–24,28,31] Details regarding sample handling, timing, and biomarkers are provided in the Supplemental Methods.

Other Collected Data

The following additional data were collected: (1) clinical data: age, sex, prestroke modified Rankin Scale (mRS) score, vascular risk factors, last-seen well and symptom onset times, baseline glycemia, baseline and 24-hour National Institutes of Health Stroke Scale score, stroke cause, and 3-month mRS score, assessed by a stroke neurologist via in-person or phone interview. Favorable outcome was defined as mRS score 0 to 2 or return to baseline, and excellent outcome as mRS score 0 to 1 or return to baseline. (2) Radiological data: baseline imaging type, occlusion site, baseline ischemic core volume (apparent diffusion coefficient $<620\times10^{-6}$ mm²/s or CBF<30%) and mismatch volume assessed by Rapid, baseline Alberta Stroke Program Early CT Score, early, and 24-hour hemorrhagic transformation per ECASS-II classification.[30] (3) Treatment data: intravenous thrombolysis administration and time, EVT puncture time, number of passes.

Statistical Analysis

This was an exploratory study with no a priori sample size calculation, given limited prior data on the association between hypoperfusion and inflammatory biomarkers; findings are hypothesis-generating.

Continuous variables were reported as medians with interquartile ranges (IQRs), and categorical variables as absolute numbers and percentages. Proportions of hypoperfusion on Tmax>6 s were reported with exact 95% CIs using the Clopper-Pearson method. Between-group comparisons of continuous variables used the Mann-Whitney *U* test; categorical comparisons used Fisher exact test.

Interrater agreement for microvascular hypoperfusion assessment was calculated using Cohen kappa coefficients. For the 3-class classification (hypoperfusion, normoperfusion, hyperperfusion), linearly weighted kappa was computed. For the binary classification (hypoperfusion versus no hypoperfusion), unweighted Cohen kappa was used; 95% CIs were calculated using the asymptotic SE.

Regarding the association between inflammatory biomarkers and hypoperfusion, Tmax>6 s hypoperfusion was chosen a priori as it provides a widely used, quantitative threshold to detect hypoperfusion.[12,14,25] Inflammatory biomarkers assessed at each time point (peripheral, central, immediate post-EVT, and 24 hours) were compared according to hypoperfusion on Tmax>6 s maps or not using the Mann-Whitney *U* tests with the Benjamini-Hochberg procedure at each time point to control the false discovery rate. Given the exploratory aim and the biomarker-to-sample size ratio, analyses were not adjusted for potential confounders. The magnitude of between-group differences was appreciated by calculating the standardized differences on rank-transformed data and was reported using forest plot. An analysis of the association between inflammatory biomarkers and microvascular hypoperfusion was also planned a priori but ultimately could not be performed due to the low number of cases with microvascular hypoperfusion.

Association between Tmax>6 s and wedge-shaped hypoperfusions and favorable outcome was assessed using Fisher exact test (no test was used for microvascular hypoperfusion due to the limited number of cases).

All statistical tests were done at the 2-tailed α-level of 0.05, and analyses were performed using IBM SPSS Statistics version 25. No imputation was performed for missing data.

Stroke FIRST PROOF ONLY

Downloaded from http://ahajournals.org by on February 11, 2026

RESULTS

Patient Characteristics

From August 15, 2023, to November 15, 2024, 318 patients with AIS due to LVO underwent EVT at Montpellier Hospital. Among them, 126 patients fulfilled the inclusion criteria for MISO, and 90 patients were enrolled (Figure S5). Baseline characteristics of patients who were enrolled and those who were not in MISO are shown in Table S1. Of the 90 enrolled patients, 19 (21%) were excluded from the analysis (technically inadequate perfusion data set [n=6], parenchymal hematoma [n=3], intracranial reocclusion [n=3], carotid stenosis or occlusion [n=3], mTICI2a recanalization after independent neuroradiologist review [n=2], and intracranial stenosis [n=2]; see flowchart, Figure 1).

Baseline and treatment characteristics of the 71 included patients are presented in Table 1. Thirty (42%) patients received intravenous thrombolysis. Median time from symptom onset to recanalization was 270 (IQR, 185–364) minutes. Median time from recanalization to early post-EVT MRP was 45 (IQR, 19–118) minutes. Final mTICI grades rated by the independent neuroradiologist were: 29 (41%) mTICI2b, 16 (23%) mTICI2c, 26 (37%) mTICI3. Imaging and clinical follow-up data are presented in Table 2.

Quantitative Assessment of Hypoperfusion on Tmax>6 s Maps

On early post-EVT MRP, 15 of 71 (21% [95% CI, 12–32]) patients exhibited persistent hypoperfusion on Tmax>6 s maps. This included 13 of 29 (45% [95% CI, 26–64]) with mTICI2b, 2 of 16 (13% [95% CI, 2–38]) with mTICI2c, and 0 of 26 (0% [95% CI, 0–13]) with mTICI3 recanalization. Median (IQR) hypoperfusion volume was 0 (0–0; Figure 2). Baseline infarct core volumes were similar between patients with and without postthrombectomy hypoperfusion on Tmax>6 s maps (19 [0–71] versus 14 [0–47] mL; Mann-Whitney *U* test U *P*=0.65). For baseline mismatch, we observed a nonsignificant difference, suggesting higher volumes in the hypoperfusion group (148 [118–180] versus 93 [48–158] mL; *P*=0.07). Favorable outcome at 3 months was observed for 7 of 15 (47%) patients with Tmax>6 s hypoperfusion compared with 34 of 54 (63%) without (*P*=0.37).

At 24 hours, quantitative hypoperfusion assessment was unavailable for 25 patients due to: nonrealization of MRP (retransferred drip-and-ship patients [n=11] or patients placed under palliative care [n=4]), parenchymal hematoma (n=6), inadequate quality MRP (n=3), reocclusion (n=1; Figure 1). Among the remaining 46 patients, none showed hypoperfusion on Tmax>6 s maps, including 9 patients with Tmax>6 s hypoperfusion on early MRP who had 24-hour perfusion MRI.

Among the 15 patients with early postthrombectomy hypoperfusion on Tmax>6 s maps, 13 underwent follow-up imaging at 24 hours (12 MRI, 1 CT; 2 patients were under palliative care). In 2 cases, the region of early hypoperfusion already corresponded to a completed infarct at baseline, precluding assessment of new infarction. Among the remaining 11 patients, 6 (55%) showed infarct extension within the area of early post-EVT hypoperfusion (an illustrative case is shown in Figure S6).

Qualitative Assessment of Wedge-Shaped Hypoperfusion and Correlation With Distal Occlusion

Wedge-shaped hypoperfusion (often with mild [<6 s] Tmax delays) was present on early postthrombectomy imaging in 36 of 71 (51%) patients: 28 of 29 (97%), 7 of 16 (44%), and 2 of 26 (8%) patients with independently assessed mTICI2b, mTICI2c and mTICI3 recanalization, respectively (including all the patients with Tmax>6 hypoperfusion, which were also wedge-shaped). In all patients, concordant distal occlusion was identified on DSA review (Figure S7), except in 2 patients (1 mTICI2c and 1 mTICI3; Figure S8). Table S2 presents the relationship between wedge-shaped hypoperfusion and both operator-assigned and independently adjudicated mTICI scores. Wedge-shaped hypoperfusions were present in 10 of 36 (28%) of operator-rated mTICI3 cases.

At 24 hours, 14 of 46 (30%) patients exhibited wedge-shaped hypoperfusion: 11 of 18 (61%), 2 of 10 (20%), and 1 of 19 (7%) patients with mTICI2b, mTICI2c, and mTICI3 recanalization, respectively. Thirteen out of these 14 patients already had wedge-shaped hypoperfusion on early imaging; the remaining patient was an mTICI3 patient who developed a new distal occlusion. Among the 24 patients with early wedge-shaped hypoperfusion and assessable 24-hour follow-up imaging, 13 (54%) had persistent hypoperfusion.

No significant difference was observed in our study regarding favorable outcomes in patients with wedge-shaped hypoperfusion compared with patients without, both at the early time window (21/36 [56%] versus 20/33 [61%], *P*=0.85), and at 24 hours (8/12 [67%] versus 23/32 [73%]; *P*=0.73).

Qualitative Assessment of Microvascular Hypoperfusion Within the Infarct Core

Interrater agreement for visual perfusion assessment on both CBV and CBF maps at the early and 24-hour time points was substantial to excellent, with linearly weighted kappa values ranging from 0.78 to 0.86 for the 3-level classification (hypoperfusion, normoperfusion, hyperperfusion), and binary kappa values ranging from 0.64 to 0.79 for hypoperfusion versus nonhypoperfusion (Table S3; Figures S9 and S10).

Stroke FIRST PROOF ONLY

Downloaded from http://ahajournals.org by on February 11, 2026

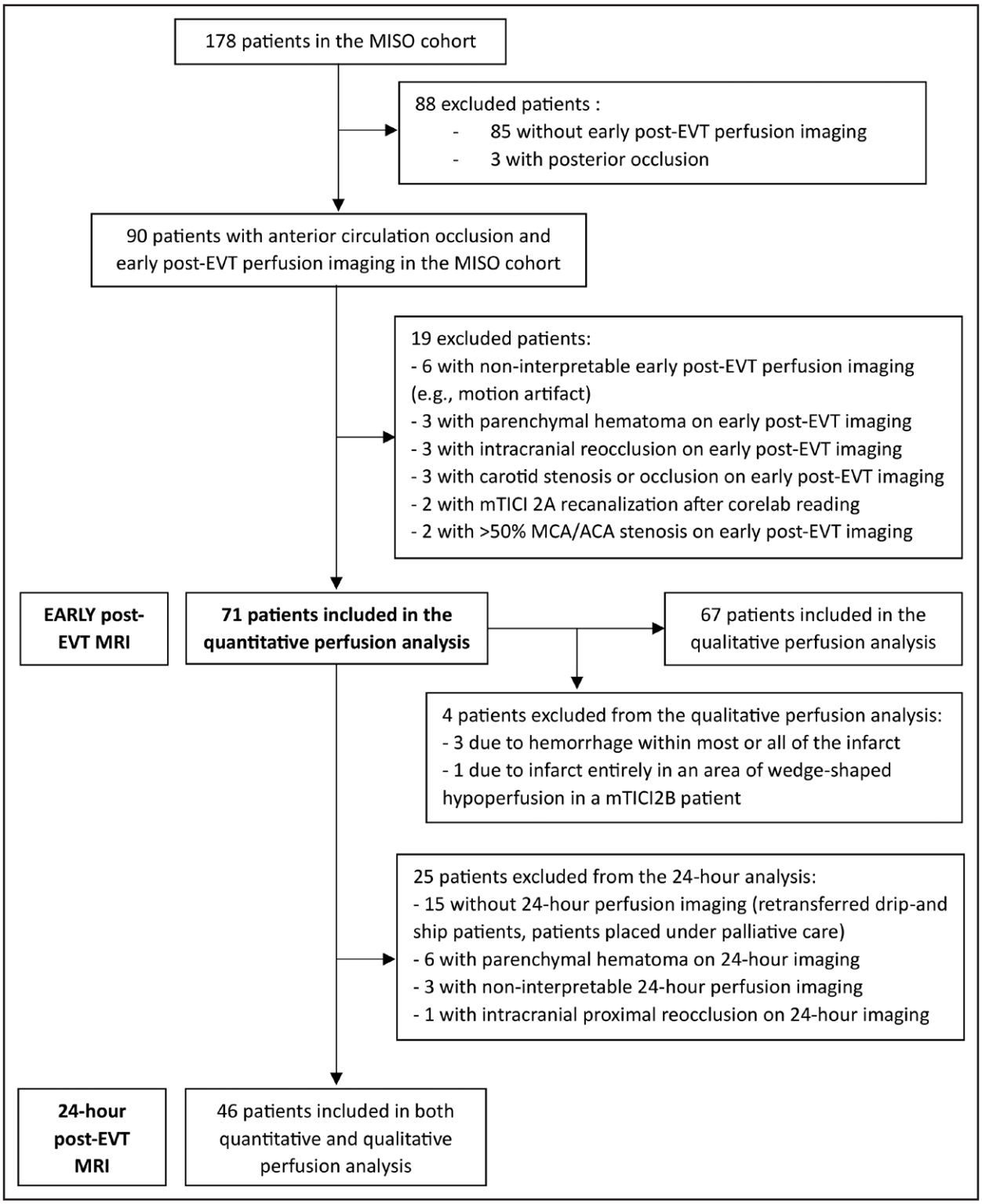

Figure 1. Flowchart.
ACA indicates anterior cerebral artery; EVT, endovascular treatment; MCA, middle cerebral artery; MISO, Multimodal Analysis of the Origin of Intracranial Thrombi; MRI, magnetic resonance imaging; and mTICI, modified Thrombolysis in Cerebral Infarction.

Visual assessment was feasible on the early MRP in 67 of 71 (94%) patients. Exclusions were due to hemorrhagic infarction occupying most of the infarct (n=3) or the infarct entirely overlapping a wedge-shaped hypoperfused area (n=1; Figures S2 through S4). After excluding the wedge-shaped hypoperfused areas associated

Downloaded from http://ahajournals.org by on February 11, 2026

Table 1. Baseline Characteristics and Treatment

Characteristics	Included patients (N=71)
Baseline clinical characteristics	
Male sex	45 (63)
Age, y	76 (67–84)
Prestroke mRS score 0–2	66 (93)
History of hypertension	42 (59)
Diabetes	6 (9)
Current smoking	10 (14)
Dyslipidemia	28 (39)
Antiplatelet therapy	21 (30)
Anticoagulant therapy	17 (24)
NIHSS score before thrombectomy	17 (9–22)
Blood glucose at admission, mmol/L	6.2 (5.7–7.3)
Prethrombectomy imaging characteristics	
Right-sided infarct	31 (44)
Baseline imaging is MRI	43 (61)
ASPECTS	8 (6–9)
Core volume, mL, n=67	15 (0–54)
Mismatch volume, mL, n=51	110 (56–162)
Intracranial occlusion site	
M1	49 (69)
M2	12 (17)
Terminal carotid	10 (14)
Treatment characteristics	
Intravenous thrombolysis use	30 (42)
Symptom onset to thrombolysis time, min, n=30	150 (122–197)
Symptom onset to puncture time, min	240 (166–337)
Puncture to recanalization time, min	28 (16–43)
General anesthesia during EVT	7 (10)
Number of passes	1 (1–2)
mTICI (independent neuroradiologist reading)	
2b	29 (41)
2c	15 (21)
3	27 (38)
Stroke cause (TOAST criteria)	
Cardioembolic	39 (55)
Atheromatous	5 (7)
Others	4 (6)
Undetermined	23 (32)

Categorical variables are expressed as n (%) and continuous variables as median (IQR). ASPECTS indicates Alberta Stroke Program Early Computed Tomography Score; EVT, endovascular treatment; IQR, interquartile range; MRI, magnetic resonance imaging; mRS, modified Rankin Scale; mTICI, modified Thrombolysis in Cerebral Infarction; NIHSS, National Institutes of Health Stroke Scale; and TOAST, Trial of ORG 10172 in Acute Stroke Treatment.

Table 2. Imaging and Clinical Follow-Up Data

Imaging and clinical follow-up data	Included patients (N=71)
Early postthrombectomy imaging	
Recanalization to imaging time, min	45 (19–118)
Hypoperfusion volume on Tmax>6 s maps, cc	0 (0–0)
Intracranial hemorrhage	
Subarachnoid hemorrhage	12 (17)
HI-1 hemorrhage	14 (20)
HI-2 hemorrhage	12 (17)
24-h postthrombectomy imaging*	
Recanalization to imaging time, h, n=67	24 (22–25)
ASPECTS, n=67	8 (7–9)
Hypoperfusion volume on Tmax>6 s maps, mL, n=46	0 (0–0)
Intracranial hemorrhage, n=67	
Subarachnoid hemorrhage	13 (19)
HI-1 hemorrhage	13 (19)
HI-2 hemorrhage	13 (19)
PH1–2 hemorrhage†	7 (11)
Clinical follow-up	
24-h NIHSS score, n=70	2 (6–13)
3-mo excellent outcome (mRS score 0–1 or baseline), n=69	32 (46)
3-mo favorable outcome (mRS score 0–2 or baseline), n=69	41 (59)
3-mo mortality, n=70	8 (11)

Categorical variables are expressed as n (%) and continuous variables as median (IQR). ASPECTS indicates Alberta Stroke Program Early Computed Tomography Score; HI, hemorrhagic infarction; IQR, interquartile range; mRS, modified Rankin Scale; NIHSS, National Institutes of Health Stroke Scale; PH, parenchymal hematoma; and Tmax, time-to-maximum.

*67 patients had 24-hour control imaging (4 did not due to placement under palliative care), of whom 25 were included in the 24-hour perfusion quantitative analysis (see flowchart).

†Patients with PH hemorrhage on early postthrombectomy imaging were excluded from the 24-hour perfusion quantitative and qualitative analyses.

Stroke FIRST PROOF ONLY

with distal occlusion, hypoperfusion within the infarct on either the CBF or CBV maps was identified in 4 (6%) patients: 1 of 26 (4%), 1 of 15 (7%), and 2 of 26 (8%) patients with mTICI2b, mTICI2c, and mTICI3 recanalization, respectively. Three patients had hypoperfusion on both CBF and CBV maps, and 1 on CBV only. None of these areas matched regions of prolonged Tmax, and in the 3 patients with available arterial spin labeling data, they appeared either normoperfused or hyperperfused. Representative cases are illustrated in Figure S11. Three of the 4 patients (75%) had a favorable outcome (mRS score 0–2) at 3 months.

On the 24-hour follow-up imaging, hypoperfusion within the infarct on CBV or CBF maps was present in 3 (7%) of 46 patients (2 on both maps, 1 on CBV maps only): 2 of these patients exhibited within-infarct hypoperfusion at the early time point (the 2 other patients with early hypoperfusion did not have 24-hour MRP), and within-infarct hypoperfusion was identified at 24 hours only in 1 patient.

Representative examples of hypoperfusion patterns identified on early postthrombectomy MRI are presented in Figure 3.

Downloaded from http://ahajournals.org by on February 11, 2026

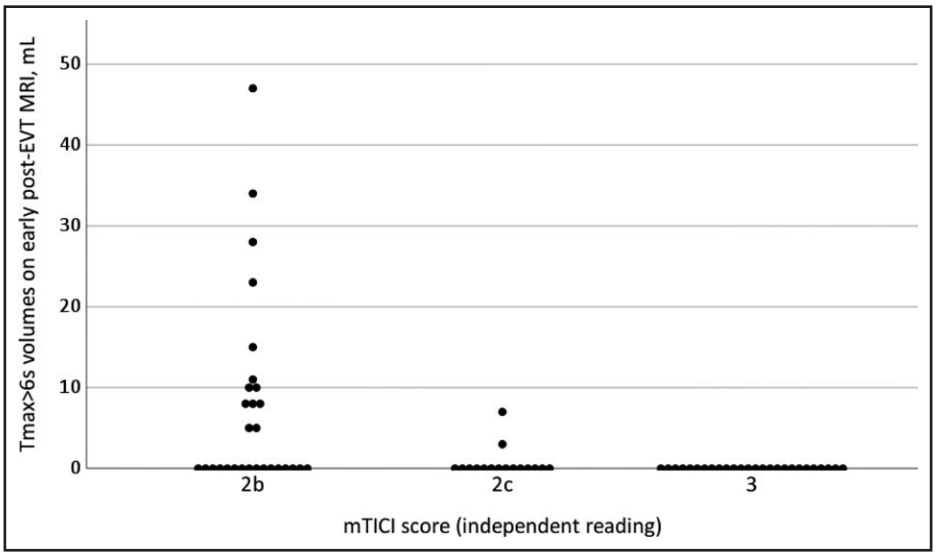

Figure 2. Time-to-maximum (Tmax) >6 s volumes on early postthrombectomy imaging according to independent modified Thrombolysis in Cerebral Infarction (mTICI) grading.
Scatterplot showing distribution of hypoperfusion volumes (Tmax>6 s) across mTICI grades. Each dot represents an individual patient. Thirteen out of 29 (45%) patients with mTICI2b and 2 out of 16 (13%) patients with mTICI2c had measurable hypoperfusion (>0 mL), whereas all patients with mTICI3 (n=26) had a volume of 0 mL. EVT indicates endovascular treatment; and MRI, magnetic resonance imaging.

Association Between Early Postthrombectomy Hypoperfusion on Tmax>6 s and Inflammatory Biomarkers

Peripheral, central, immediate postthrombectomy, and 24-hour blood samples were available for 70, 41, 69, and 57 patients, respectively. Several biomarkers showed associations with Tmax>6 s hypoperfusion presence at different time points, with consistently higher levels observed in the hypoperfusion group: CCL (C-C motif ligand chemokine) 3 (P=0.011), IL (interleukin)-8 (P=0.014), and eotaxin (P=0.017) at the peripheral time point, CCL22 at the central time point (P=0.032), and again CCL3 immediately after EVT (P=0.028; Figure 4; Figures S12 through S15). At 24 hours, no biomarker reached significance. However, none of these associations at any time point remained statistically significant after the false discovery rate correction was applied.

DISCUSSION

In this prospective study of 71 patients with AIS due to anterior LVO successfully recanalized by EVT and evaluated using early postthrombectomy MRP, 4 key findings emerged. First, early persistent Tmax>6 s hypoperfusions were associated with lower mTICI scores, were rare in patients with near-complete (mTICI2c) or complete (mTICI3) reperfusion, and resolved for all patients by 24 hours. Second, wedge-shaped hypoperfusions were common in mTICI2b patients on early imaging, decreased markedly at 24 hours, and helped identify residual distal occlusions in a sizeable fraction of patients initially graded as mTICI 2c-3. Third, after rigorous exclusion of confounding factors, persistent early hypoperfusion on CBV/CBF maps within the ischemic territory, suggestive of no-reflow, was rare (6%). Fourth, no robust associations were found between post-EVT Tmax>6 s hypoperfusion and systemic inflammatory biomarkers, whether sampled centrally or peripherally.

On early post-EVT imaging, Tmax>6 s hypoperfusions were observed in 21% of patients, with prevalence decreasing as recanalization improved (45% in mTICI2b, 13% in mTICI2c, absent in mTICI3). In contrast, Horie et al[25] reported an 80% prevalence of Tmax>6 s–defined hypoperfusions on flat-panel CT perfusion 30 minutes after successful EVT, whereas Rubiera et al[12] found a 63% rate in mTICI2b and a 40% rate in mTICI3 patients using conventional CT perfusion within a similar timeframe. Reported volumes also varied widely, from large in Horie et al[25] (mean, 60–80 mL) to minimal in Rubiera et al[12] (median, 0 [IQR, 0–7] mL in mTICI3).[12,25] Discrepancies likely reflect methodological differences. First, both studies used CT perfusion, with postangiographic early contrast accumulation potentially impacting Tmax reliability. Second, neither study systematically excluded alternative causes of hypoperfusion. Third, in Rubiera et al,[12] the mTICI grading was assessed by the operator, which is prone to overestimation.[26,32] Fourth, Horie et al[25] relied on flat-panel CT perfusion, and it is not clear whether Tmax artifacts were removed. Of note, another study, using early (<2 hours) post-EVT MRP, reported similarly small Tmax>6 s volumes across mTICI subgroups, in line with our findings.[33]

Importantly, both Tmax>6 s and wedge-shaped hypoperfusions likely reflect a common mechanism: persistent distal occlusions (all Tmax>6 s hypoperfusions in

Stroke FIRST PUBLISHED ONLINE

Downloaded from http://ahajournals.org by on February 11, 2026

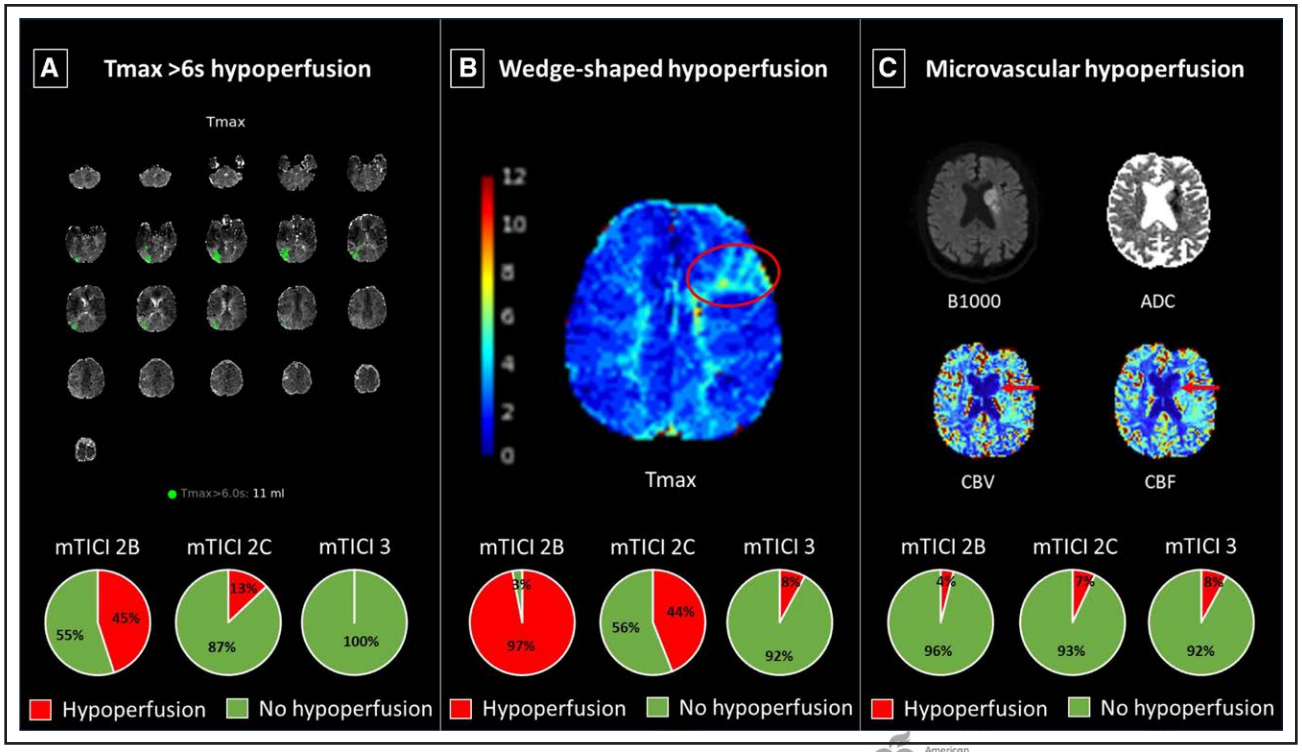

Figure 3. Representative examples of hypoperfusion patterns identified on early postthrombectomy magnetic resonance imaging with distribution across modified Thrombolysis in Cerebral Infarction (mTICI) grades.
Representative examples of early postendovascular treatment hypoperfusion patterns: (**A**) time-to-maximum (Tmax) >6 s hypoperfusion volume, (**B**) wedge-shaped hypoperfusion on Tmax maps (red circle), and (**C**) microvascular hypoperfusion (red arrows). For each pattern, the distribution of patients according to independent mTICI grading (2b, 2c, and 3) is displayed in pie charts below, indicating the proportion with (red) or without (green) hypoperfusion. ADC indicates apparent diffusion coefficient; CBF, cerebral blood flow; and CBV, cerebral blood volume.

Stroke FIRST PROOF ONLY

our study were also classified as wedge-shaped hypoperfusions). Although Tmax>6 s provides a quantitative, threshold-based assessment of significant macrovascular delays, wedge-shaped hypoperfusions, visually assessed without fixed thresholds, offer greater sensitivity to subtle perfusion deficits.[26] In our cohort, early wedge-shaped hypoperfusions correlated strongly with independent mTICI grades (97% in 2b, 44% in 2c, 8% in 3), consistent with a flat-panel CT perfusion study, where they matched eTICI scores in 81% of patients.[26] Interestingly, they were observed in 10 of 36 (28%) of operator-rated mTICI3 and 2 of 26 (8%) of independently rated mTICI3 cases (Table S2), almost always corresponding to a distal occlusion on DSA review. Only 2 patients (1 mTICI2c, 1 mTICI3) had wedge-shaped hypoperfusion without any visible occlusion on final DSA, possibly reflecting angiographically occult emboli; neither developed infarction at 24 hours (Figure S8).[26] These findings underscore the utility of early perfusion imaging in detecting subtle distal occlusion. Such imaging could guide future trials of adjunctive postrecanalization intra-arterial therapies. Notably, among postrecanalization thrombolysis trials, only those including mTICI2b patients demonstrated benefit, suggesting these agents may preferentially target residual distal emboli rather than no-reflow.[34–39]

One strength of our study lies in its prospective serial perfusion imaging design, allowing evaluation of the temporal evolution of postrecanalization perfusion deficits. At 24 hours, no patient had persistent Tmax>6 s hypoperfusion, consistent with prior reports showing low (7%) residual deficits in mTICI3 patients.[40,41] Wedge-shaped abnormalities also substantially regressed, with a delayed reperfusion observed in 11 of 24 patients with early wedge-shaped hypoperfusion and 24-hour assessable follow-up. Residual wedge-shaped hypoperfusions persisted in 61%, 20%, and 7% of mTICI 2b, 2c, and 3 patients, respectively, in line with another study reporting 50%, 17%, and 0% of persistent Tmax>4 s deficits.[42] To our knowledge, only 1 other study has provided serial MRI perfusion data at both early and 24-hour time points post-EVT using Tmax maps.[15] Although focusing primarily on postischemic hyperemia, it reported residual hypoperfusion in 61% of patients at baseline and 38% at 24 hours. However, alternative causes were not excluded, Tmax>6 s volumes were not quantified, and associations with mTICI were not analyzed.[27] Our study, therefore, provides quantitative evidence that most early perfusion abnormalities resolve over time and are likely attributable to distal emboli.

In the present study, we developed a novel methodological approach, derived from recommendations

Downloaded from http://ahajournals.org by on February 11, 2026

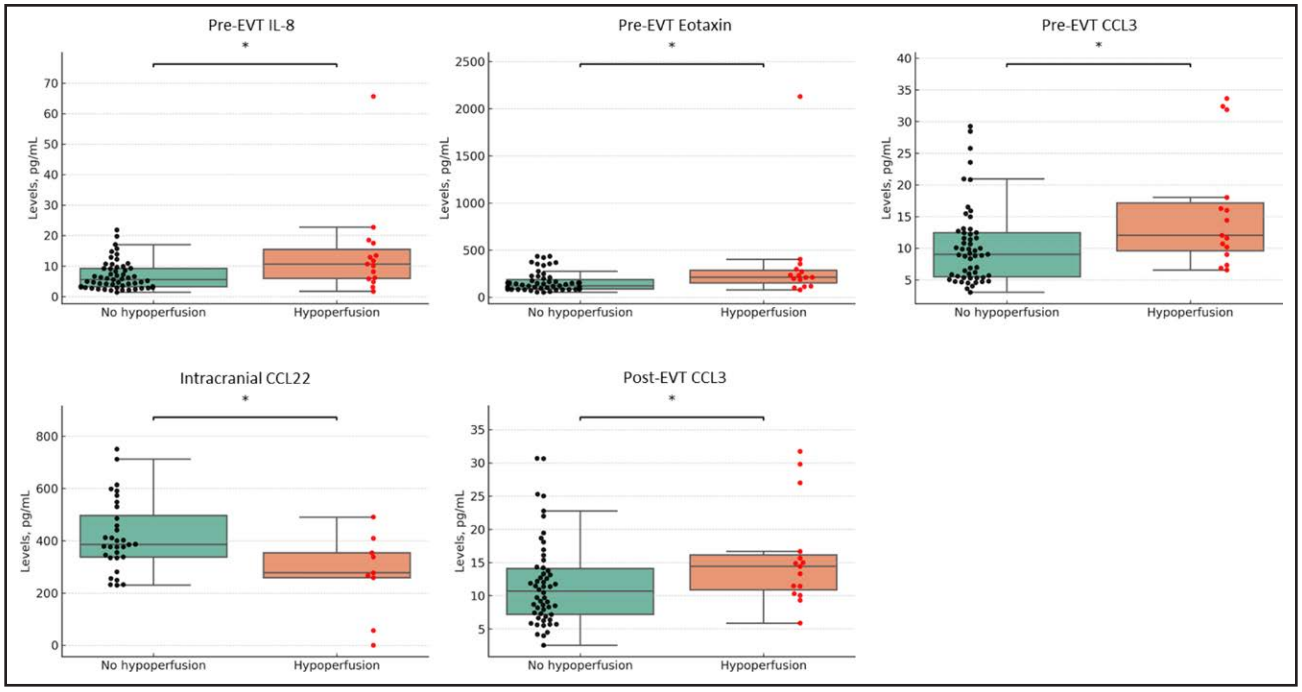

Figure 4. Peripheral and intracranial biomarkers associated with early postthrombectomy hypoperfusion on time-to-maximum (Tmax) >6 s maps in univariate analysis before false discovery rate (FDR) correction.
Boxplots showing distribution of biomarker levels in patients with and without early postthrombectomy hypoperfusion on Tmax>6 s maps. Data are presented as box-and-whisker plots (median, interquartile range, and range), with individual values overlaid. The figure displays the biomarkers that were significantly associated with hypoperfusion in univariate analysis, before FDR correction: pre-endovascular treatment (EVT) IL (interleukin)-8, pre-EVT eotaxin, pre-EVT CCL (chemokine CC-motif ligand; also known as MIP1-α [macrophage inflammatory protein alpha]) 3, intracranial CCL22 (also known as MDC [macrophage-derived chemokine]), and post-EVT CCL3 (Figures S12 through S15).

Stroke FIRST PROOF ONLY

expressed in our previous systematic review,[14] to assess microvascular hypoperfusion potentially related to no-reflow, by rigorously excluding alternative causes (hemorrhage, stenosis, proximal reocclusion), and wedge-shaped hypoperfusions linked to distal emboli. This strategy, which showed good interrater reproducibility, enabled the investigation of microvascular hypoperfusion abnormalities in mTICI 2b-2c patients. Using this methodology, we showed that microvascular hypoperfusion within the infarct on CBV/CBF maps was rare (6%). Reported prevalence of microvascular hypoperfusion, mostly explored at 24 hours only, is highly variable (0%–43%),[7–15] largely due to inconsistent definitions and heterogeneous exclusion of confounding factors, with a lower prevalence in studies focusing on mTICI3 patients only and excluding confounding factors.[14] Hence, a study that included mTICI3 patients, excluded alternative causes of hypoperfusion, and used a similar visual definition of hypoperfusion on CBV/CBF maps within the infarct at 24 hours, found a 6% rate of hypoperfusion on both CBV and CBF, consistent with our results.[11] Conversely, Ng et al[10] reported a 25% within-infarct hypoperfusion rate on CBF or CBV maps, confirmed by >15% asymmetry compared with contralateral regions.[7] Although their methodology excluded the hemorrhagic component of the infarct, peri-hematoma tissue was still considered, likely contributing to overestimation of no-reflow. Of note, they reported a strong association between no-reflow and hemorrhagic transformation, potentially suggesting that perfusion abnormalities were linked to bleeding areas. Interestingly, no patient in our cohort had hemorrhage at 24 hours within areas of early microvascular hypoperfusion. In contrast, 24-hour hemorrhagic transformation developed in regions that were initially normoperfused or hyperperfused, with secondary hypoperfusion appearing around hematomas (Figure S4). This temporal pattern is inconsistent with the pathophysiology of no-reflow as shown in animal studies, in which no-reflow is already present immediately after recanalization,[16–18,21] and suggests that perilesional hypoperfusion reflects artifacts or secondary reactive changes rather than true no-reflow.[43,44] Finally, a recent study of 33 mTICI 2c-3 patients without hemorrhage or stenosis reported a 24% rate of within-infarct hypoperfusion on early (<2 hours) MRI,[27] but distal emboli were not excluded, and prevalence was higher in mTICI2c cases.[27]

Importantly, although microvascular hypoperfusion was infrequent, distinguishing it from distal occlusions remains clinically relevant. The 2 mechanisms differ conceptually and therapeutically: distal emboli may be addressed with optimized thrombectomy techniques or adjunctive thrombolysis,[34–39] whereas no-reflow may represent a distinct therapeutic entity, with strategies including prevention of capillary failure, restoration of capillary

Downloaded from http://ahajournals.org by on February 11, 2026

perfusion, and promotion of venous outflow.[20–22,24,45] This distinction justifies continued investigation despite the low prevalence observed in our limited sample. Further large prospective studies with harmonized definitions are warranted.

At the same time, our findings suggest that what is currently labeled as no-reflow on perfusion imaging may not faithfully reflect true microvascular dysfunction. Most CBV or CBF abnormalities did not correspond to delayed perfusion on mean transit time maps, and among patients with arterial spin labeling imaging, perfusion appeared normal or even elevated in these regions (Figure S11). Hence, the so-called no-reflow could instead represent alternative mechanisms, such as vasogenic edema or yet unidentified processes. Only studies combining perfusion imaging and histopathologic validation in nonhuman primates or directly in humans could resolve this puzzling issue.

Finally, we investigated the association between post-EVT Tmax>6 s hypoperfusion and inflammatory biomarkers, including central samples obtained distal to the clot—a finding not previously reported. Some nominal associations were noted (CCL3, IL-8, eotaxin, CCL22), but none survived correction for multiple comparisons. This likely reflects limited power and the predominantly mechanical origin of hypoperfusion in our cohort, strongly linked to the degree of angiographic recanalization. Given the low prevalence of microvascular hypoperfusion, statistical analysis for this imaging phenotype could not be performed, and its relationship with biomarkers may remain difficult to capture in future studies. An alternative approach would be to investigate an association between biomarkers and futile recanalization. Using this methodology, Mechtouff et al[46] demonstrated that elevated peripheral blood IL-6 levels at 24 hours were independently associated with futile recanalization. However, futile recanalization encompasses multiple overlapping mechanisms, such as large core, edema, delayed infarct progression, and hemorrhagic transformation, complicating interpretation.[19]

Our study has several limitations. First, it was conducted in a single comprehensive stroke center with a moderate sample size, which may reduce generalizability. Second, not all patients fulfilling the inclusion criteria were enrolled in the cohort due to logistical constraints. Third, 24-hour imaging was not available for all patients, and no systematic imaging was performed after this time point, limiting the serial assessment. Fourth, the infarct core was defined on the 24-hour MRI, or on the early postthrombectomy MRI when the former was not available, based primarily on B1000 diffusion-weighted imaging maps. This approach may have underestimated the true infarct extent due to potential transient reversal of diffusion signal within the first 24 hours after recanalization, and ongoing infarct growth that can occur beyond 24 hours.[47,48] Fifth, the study may have been underpowered to detect subtle associations between inflammatory biomarkers and hypoperfusion. Sixth, similarly, this lack of power could explain the absence of a relation between all types of hypoperfusion and clinical outcomes, contrary to other studies.[7,14,25,26] Of note, a trend was observed for poorer outcomes in patients with Tmax>6 s hypoperfusion.

CONCLUSIONS

In conclusion, this prospective study offers novel insights into postthrombectomy cerebral perfusion through early MRI, using a rigorous methodology that enabled precise discrimination between macrovascular and microvascular perfusion deficits. Early imaging proved particularly useful in detecting subtle or missed distal occlusions, even in patients with apparently complete recanalization, with potential impact on future therapeutic strategies and trial design. When confounding factors were meticulously excluded, true tissue-level hypoperfusion was rare. Importantly, this is the first study to investigate the association between early perfusion abnormalities and inflammatory biomarkers; no robust relationship was found, reinforcing the predominantly mechanical origin of early post-EVT hypoperfusion. Further research is warranted, particularly in patients with longer occlusion durations, where no-reflow may be more prevalent, as in animal studies.

Stroke FIRST PROOF ONLY

ARTICLE INFORMATION

Received July 01, 2025; final revision received December 13, 2025; accepted December 18, 2025.

Presented in part at the International Stroke Conference, New Orleans, LA, February 4–6, 2026.

Affiliations

Neurology Department (A.t.S., T.R., L.C., I.M., X.A., C.A., V.C.), Neuroradiology Department (C.D., M. Moynier, G.G., P.H.L., F.C., T.C., F.-L.C., Q.V.), and Department of Anesthesiology and Critical Care Medicine, Gui de Chauliac Hospital (F.R.), Montpellier University Hospital, France. Department of Neurology, Stanford Stroke Center, CA (A.t.S., N.Y., S.C., M. Mlynash, M.G.L., G.W.A.). Institute of Functional Genomics, University of Montpellier, Centre National de la Recherche Scientifique (CNRS), Institut National de la Santé et de la Recherche Médicale (INSERM), France (A.t.S., C.D., N.M., M.B., V.C.). Institut de Psychiatrie et Neurosciences de Paris, U1266, Institut National de la Santé et de la Recherche Médicale (INSERM), France (A.t.S., P.S., J.-C.B.). Neurology Department, Hôpital Fondation Adolphe de Rothschild, Paris, France (P.S.). Department of Biostatistics, Centre Hospitalier Universitaire (CHU) Lille, France (J.L.). Radiology Department, Stanford University, Palo Alto, CA (J.J.H.). Centre National de la Recherche Scientifique (CNRS), L2C, University of Montpellier, France (E.L.B.). Department of Neurology, Acute Stroke Unit, Hôpital Pierre-Paul Riquet, Centre Hospitalier Universitaire (CHU) Toulouse, France (J.-M.O.). Neurology Department, Groupe Hospitalier Paris Psychiatrie et Neurosciences, Université Paris Cité, France (J.-C.B.).

Sources of Funding

This study was funded by the "Fondation pour la Recherche sur l'AVC" (FRM AVC202408019937). Dr Ter Schiphorst received grants from the Fulbright Program, the Monahan Foundation, the France-Stanford Center for Interdisciplinary Studies, the Philippe Foundation, and Rotary International.

Disclosures

Dr Albers reports stock holdings in iSchemaView and compensation from Biogen, iSchemaView, and Genentech for consultant services. Dr Arquizan reports

Downloaded from http://ahajournals.org by on February 11, 2026

compensation from Novartis for consultant services. Dr Baron reports compensation from Frontiers in Neurology for other services. Dr Christensen reports stock holdings in Ischemaview and employment by Cercare Medical. Dr Costalat reports compensation from Penumbra, Inc, MicroVention, Inc, Balt USA, LLC, Stryker Corporation, Medtronic USA, Inc, and Johnson & Johnson Health Care Systems, Inc, for consultant services. Dr Heit reports consulting fees from Medtronic and MicroVention, stock holdings in Dragon Vascular, and is a member of the Medical and Scientific Advisory Board of iSchemaView. Dr Lansberg reports grants from the National Institute of Neurological Disorders and Stroke. Dr Olivot reports compensation from Roche Diagnostics International, Ltd for consultant services and compensation from Bristol Myers Squibb for consultant services. The other authors report no conflicts.

Supplemental Material

Supplemental Methods
Tables S1–S3
Figures S1–S15
STROBE Checklist

REFERENCES

1. Goyal M, Menon BK, van Zwam WH, Dippel DWJ, Mitchell PJ, Demchuk AM, Dávalos A, Majoie CBLM, van der Lugt A, de Miquel MA, et al; HERMES Collaborators. Endovascular thrombectomy after large-vessel ischaemic stroke: a meta-analysis of individual patient data from five randomised trials. *Lancet*. 2016;387:1723–1731. doi: 10.1016/S0140-6736(16)00163-X
2. Shahid AH, Abbasi M, Larco JLA, Madhani SI, Liu Y, Brinjikji W, Savastano LE. Risk factors of futile recanalization following endovascular treatment in patients with large-vessel occlusion: systematic review and meta-analysis. *Stroke Vasc Interv Neurol*. 2022;2:e000257. doi: 10.1161/svin.121.000257
3. Nie X, Pu Y, Zhang Z, Liu X, Duan W, Liu L. Futile recanalization after endovascular therapy in acute ischemic stroke. *Biomed Res Int*. 2018;2018:5879548. doi: 10.1155/2018/5879548
4. De Silva DA, Fink JN, Christensen S, Ebinger M, Bladin C, Levi CR, Parsons M, Butcher K, Barber PA, Donnan GA, et al; Echoplanar Imaging Thrombolytic Evaluation Trial (EPITHET) Investigators. Assessing reperfusion and recanalization as markers of clinical outcomes after intravenous thrombolysis in the Echoplanar Imaging Thrombolytic Evaluation Trial (EPITHET). *Stroke*. 2009;40:2872–2874. doi: 10.1161/STROKEAHA.108.543595
5. Eilaghi A, Brooks J, d'Esterre C, Zhang L, Swartz RH, Lee TY, Aviv RI. Reperfusion is a stronger predictor of good clinical outcome than recanalization in ischemic stroke. *Radiology*. 2013;269:240–248. doi: 10.1148/radiol.13122327
6. Cho TH, Nighoghossian N, Mikkelsen IK, Derex L, Hermier M, Pedraza S, Fiehler J, Østergaard L, Berthezène Y, Baron JC. Reperfusion within 6 hours outperforms recanalization in predicting penumbra salvage, lesion growth, final infarct, and clinical outcome. *Stroke*. 2015;46:1582–1589. doi: 10.1161/STROKEAHA.114.007964
7. Rivet S, Churilov L, Yassi N, Kleinig TJ, Thijs V, Wu T, Dewey H, Desmond PM, Parsons MW, Donnan GA, et al. Persistent tissue-level hypoperfusion (no-reflow) negates the clinical benefit of successful thrombectomy. *Stroke*. 2025;56:1451–1459. doi: 10.1161/STROKEAHA.124.049574
8. Ter Schiphorst A, Charron S, Hassen WB, Provost C, Naggara O, Benzakoun J, Seners P, Turc G, Baron JC, Oppenheim C. Tissue no-reflow despite full recanalization following thrombectomy for anterior circulation stroke with proximal occlusion: a clinical study. *J Cerebr Blood Flow Metab*. 2021;41:253–266. doi: 10.1177/0271678X20954929
9. Ter Schiphorst A, Oppenheim C, Baron JC. Reader response: prevalence and significance of impaired microvascular tissue reperfusion despite macrovascular angiographic reperfusion (no-reflow). *Neurology*. 2023;100:217–218. doi: 10.1212/WNL.0000000000206786
10. Ng FC, Churilov L, Yassi N, Kleinig TJ, Thijs V, Wu T, Shah D, Dewey H, Sharma G, Desmond P, et al. Prevalence and significance of impaired microvascular tissue reperfusion despite macrovascular angiographic reperfusion (no-reflow). *Neurology*. 2021;98:e790–e801. doi: 10.1212/WNL.0000000000013210
11. Mujanovic A, Imhof A, Zheng S, Piechowiak EI, Serrallach BL, Meinel TR, Dobrocky T, Aziz YN, Seiffge DJ, Goeldlin M, et al. Perfusion abnormalities on 24-hour perfusion imaging in patients with complete endovascular reperfusion. *Stroke*. 2024;55:2315–2324. doi: 10.1161/STROKEAHA.124.047441
12. Rubiera M, Garcia-Tornel A, Olivé-Gadea M, Campos D, Requena M, Vert C, Pagola J, Rodriguez-Luna D, Muchada M, Boned S, et al. Computed tomography perfusion after thrombectomy: an immediate surrogate marker of outcome after recanalization in acute stroke. *Stroke*. 2020;51:1736–1742. doi: 10.1161/STROKEAHA.120.029212
13. Luijten SPR, Bos D, van Doormaal PJ, Goyal M, Dijkhuizen RM, Dippel DWJ, Roozenbeek B, van der Lugt A, Warnert EAH. Cerebral blood flow quantification with multi-delay arterial spin labeling in ischemic stroke and the association with early neurological outcome. *Neuroimage Clin*. 2023;37:103340. doi: 10.1016/j.nicl.2023.103340
14. ter Schiphorst A, Turc G, Hassen WB, Oppenheim C, Baron JC. Incidence, severity and impact on functional outcome of persistent hypoperfusion despite large-vessel recanalization, a potential marker of impaired microvascular reperfusion: systematic review of the clinical literature. *J Cereb Blood Flow Metab*. 2024;44:38–49. doi: 10.1177/0271678X231209069
15. Luby M, Hsia AW, Lomahan CA, Davis R, Burton S, Kim Y, Craft V, Uche V, Cabatbat R, Adil MM, et al. Post-ischemic hyperemia following endovascular therapy for acute stroke is associated with lesion growth. *J Cereb Blood Flow Metab*. 2023;43:856–868. doi: 10.1177/0271678x231155222
16. Ames A, Wright RL, Kowada M, Thurston JM, Majno G. Cerebral ischemia. II. The no-reflow phenomenon. *Am J Pathol*. 1968;52:437–453.
17. Crowell RM, Olsson Y. Impaired microvascular filling after focal cerebral ischemia in monkeys. *J Neurosurg*. 1972;36:303–309. doi: 10.3171/jns.1972.36.3.0303
18. Little JR, Kerr FW, Sundt TM. Microcirculatory obstruction in focal cerebral ischemia. Relationship to neuronal alterations. *Mayo Clin Proc*. 1975;50:264–270.
19. Baron JC. Is reperfusion injury a largely intra-ischemic injury? *Stroke*. 2025;56:777–782. doi: 10.1161/STROKEAHA.124.049541
20. Yemisci M, Gursoy-Ozdemir Y, Vural A, Can A, Topalkara K, Dalkara T. Pericyte contraction induced by oxidative-nitrative stress impairs capillary reflow despite successful opening of an occluded cerebral artery. *Nat Med*. 2009;15:1031–1037. doi: 10.1038/nm.2022
21. Dalkara TP. A novel target to improve success of recanalization therapies. *Stroke*. 2019;50:2985–2991. doi: 10.1161/STROKEAHA.118.023590
22. Desilles J, Syvannarath V, Di Meglio L, Ducroux C, Boisseau W, Louedec L, Jandrot-Perrus M, Michel J, Mazighi M, Ho-Tin-Noé B. Downstream microvascular thrombosis in cortical venules is an early response to proximal cerebral arterial occlusion. *J Am Heart Assoc*. 2018;7:e007804. doi: 10.1161/jaha.117.007804
23. Sperring CP, Savage WM, Argenziano MG, Leifer VP, Alexander J, Echlov N, Spinazzi EF, Connolly ES. No-reflow post-recanalization in acute ischemic stroke: mechanisms, measurements, and molecular markers. *Stroke*. 2023;54:2472–2480. doi: 10.1161/strokeaha.123.044240
24. Sun F, Zhou J, Chen X, Yang T, Wang G, Ge J, Zhang Z, Mei Z. No-reflow after recanalization in ischemic stroke: From pathomechanisms to therapeutic strategies. *J Cereb Blood Flow Metab*. 2024;44:857–880. doi: 10.1177/0271678X241237159
25. Horie N, Inoue M, Morimoto T, Sadakata E, Okamura K, Morofuji Y, Hara T, Kuwabara M, Kondo H, Ishii D. Recanalization does not always equate to reperfusion: no-reflow phenomenon after successful thrombectomy. *Stroke*. 2024;56:183–189. doi: 10.1161/strokeaha.124.048994
26. Mujanovic A, Kurmann CC, Manhart M, Piechowiak EI, Pilgram-Pastor SM, Serrallach BL, Boulouis G, Meinel TR, Seiffge DJ, Jung S, et al. Value of immediate flat panel perfusion imaging after endovascular therapy (AFTER-MATH): a proof of concept study. *AJNR Am J Neuroradiol*. 2024;45:163–170. doi: 10.3174/ajnr.A8103
27. Valls Carbó A, Palomar A, Laredo C, Werner M, Dorado L, Remollo S, Munuera J, Puig J, Silva Y, Pérez de la Ossa N, et al. Relevance of persistent perfusion deficits on clinical outcomes after successful endovascular treatment: a prospective serial magnetic resonance study. *Front Neurol*. 2025;16:1478240. doi: 10.3389/fneur.2025.1478240
28. Dargazanli C, Blaquière M, Moynier M, de Bock F, Labreuche J, Ter Schiphorst A, Derraz I, Radu RA, Gascou G, Lefevre PH, et al. Inflammation biomarkers in the intracranial blood are associated with outcome in patients with ischemic stroke. *J. Neurointerventional Surg*. 2024;17:159–166. doi: 10.1136/jnis-2023-021365
29. von EE, Altman DG, Egger M, Pocock SJ, Gøtzsche PC, Vandenbroucke JP. Strengthening the Reporting of Observational Studies in Epidemiology (STROBE) statement: guidelines for reporting observational studies. *BMJ*. 2007;335:806–808. doi: 10.1016/S0140-6736(07)61602-X
30. Hacke W, Kaste M, Fieschi C, von Kummer R, Davalos A, Meier D, Larrue V, Bluhmki E, Davis S, Donnan G, et al. Randomised double-blind placebo-controlled trial of thrombolytic therapy with intravenous alteplase

Downloaded from http://ahajournals.org by on February 11, 2026

Stroke FIRST PROOF ONLY

in acute ischaemic stroke (ECASS II). *Lancet*. 1998;352:1245–1251. doi: 10.1016/s0140-6736(98)08020-9

31. Dagonnier M, Donnan GA, Davis SM, Dewey HM, Howells DW. Acute stroke biomarkers: are we there yet? *Front Neurol*. 2021;12:619721. doi: 10.3389/fneur.2021.619721
32. Zhang G, Treurniet KM, Jansen IGH, Emmer BJ, van den Berg R, Marquering HA, Uyttenboogaart M, Jenniskens SFM, Roos YBWEM, van Doormaal PJ, et al; MR CLEAN Registry Investigators. Operator versus core lab adjudication of reperfusion after endovascular treatment of acute ischemic stroke. *Stroke*. 2018;49:2376–2382. doi: 10.1161/STROKEAHA.118.022031
33. Hernández-Pérez M, Werner M, Remollo S, Martín C, Cortés J, Valls A, Ramos A, Dorado L, Serena J, Munuera J, et al. Early and delayed infarct growth in patients undergoing mechanical thrombectomy: a prospective, serial MRI study. *Stroke*. 2023;54:217–225. doi: 10.1161/STROKEAHA.122.039090
34. Renú A, Millán M, San Román L, Blasco J, Martí-Fàbregas J, Terceño M, Amaro S, Serena J, Urra X, Laredo C, et al; CHOICE Investigators. Effect of intra-arterial alteplase vs placebo following successful thrombectomy on functional outcomes in patients with large vessel occlusion acute ischemic stroke: the CHOICE randomized clinical trial. *JAMA*. 2022;327:826–835. doi: 10.1001/jama.2022.1645
35. Yang X, He X, Pan D, Xu Y, Peng H, Li K, Zhang M, Zhu Y, Chen Y, He B, et al. Intra-arterial alteplase for acute ischaemic stroke after mechanical thrombectomy (PEARL): rationale and design of a multicentre, prospective, open-label, blinded-endpoint, randomised controlled trial. *BMJ Open*. 2024;14:e091059. doi: 10.1136/bmjopen-2024-091059
36. Huo X, Luo G, Sun D, Nguyen T, Abdalkader M, Chen W, Yao X, Yuan G, Yi T, Han H, et al. Intra-arterial tenecteplase after successful endovascular therapy (ANGEL-TNK): protocol of a multicentre, open-label, blinded endpoint, prospective, randomised trial. *Stroke Vasc Neurol*. 2024;10:508–513. doi: 10.1136/svn-2024-003318
37. Huang J, Yang J, Liu C, Li L, Yang D, Guo C, Zeng G, Song J, Ma J, Xu X, et al; POST-TNK Investigators. Intra-arterial tenecteplase following endovascular reperfusion for large vessel occlusion acute ischemic stroke: the POST-TNK randomized clinical trial. *JAMA*. 2025;333:579–588. doi: 10.1001/jama.2024.23466
38. Liu C, Guo C, Li F, Yu N, Huang J, Peng Z, Kong W, Song J, Liu X, Fan S, et al; POST-UK Investigators. Intra-arterial urokinase after endovascular reperfusion for acute ischemic stroke: the POST-UK randomized clinical trial. *JAMA*. 2025;333:589–598. doi: 10.1001/jama.2024.23480
39. Hou X, Huang J, Wang L, He Y, Song J, Guo C, Yang S, Shi X, Chen L, Liu Q, et al. Intra-arterial tenecteplase after successful reperfusion in large vessel occlusion stroke: a randomized clinical trial. *JAMA Neurol*. 2025;82:895–904. doi: 10.1001/jamaneurol.2025.2036
40. Albers GW, Goyal M, Jahan R, Bonafe A, Diener HC, Levy EI, Pereira VM, Cognard C, Yavagal DR, Saver JL. Relationships between imaging assessments and outcomes in Solitaire with the intention for thrombectomy as primary endovascular treatment for acute ischemic stroke. *Stroke*. 2015;46:2786–2794. doi: 10.1161/STROKEAHA.115.010710
41. Luby M, Merino JG, Davis R, Ansari S, Fisher M, Hsia AW, Kim Y, Latour LL, McCreedy ES, Singh RS, et al. Association of multiple passes during mechanical thrombectomy with incomplete reperfusion and lesion growth. *Cerebrovasc Dis*. 2022;51:394–402. doi: 10.1159/000519796
42. Mujanovic A, Jungi N, Kurmann CC, Dobrocky T, Meinel TR, Almiri W, Grunder L, Beyeler M, Lang MF, Jung S, et al. Importance of delayed reperfusions in patients with incomplete thrombectomy. *Stroke*. 2022;53:3350–3358. doi: 10.1161/STROKEAHA.122.040063
43. Fainardi E, Borrelli M, Saletti A, Schivalocchi R, Azzini C, Cavallo M, Ceruti S, Tamarozzi R, Chieregato A. CT perfusion mapping of hemodynamic disturbances associated to acute spontaneous intracerebral hemorrhage. *Neuroradiology*. 2008;50:729–740. doi: 10.1007/s00234-008-0402-x
44. Schellinger PD, Fiebach JB, Hoffmann K, Becker K, Orakcioglu B, Kollmar R, Jüttler E, Schramm P, Schwab S, Sartor K, et al. Stroke MRI in intracerebral hemorrhage. *Stroke*. 2003;34:1674–1679. doi: 10.1161/01.STR.0000076010.10696.55
45. Faizy TD, Mlynash M, Marks MP, Christensen S, Kabiri R, Kuraitis GM, Broocks G, Winkelmeier L, Geest V, Nawabi J, et al. Intravenous tPA (tissue-type plasminogen activator) correlates with favorable venous outflow profiles in acute ischemic stroke. *Stroke*. 2022;53:3145–3152. doi: 10.1161/STROKEAHA.122.038560
46. Mechtouff L, Bochaton T, Paccalet A, Da Silva CC, Buisson M, Amaz C, Derex L, Ong E, Berthezene Y, Eker OF, et al. Association of interleukin-6 levels and futile reperfusion after mechanical thrombectomy. *Neurology*. 2021;96:e752–e757. doi: 10.1212/WNL.0000000000011268
47. Ospel JM, Rex N, Oueidat K, McDonough R, Rinkel L, Baird G, Collins S, Jindal G, Alvin MD, Boxerman J, et al. Infarcts due to large vessel occlusions continue to grow despite near-complete reperfusion after endovascular treatment. *J Stroke*. 2024;26:260–268. doi: 10.5853/jos.2023.02621
48. Bala F, Ospel J, Mulpur B, Kim BJ, Yoo J, Menon BK, Goyal M, Federau C, Sohn SI, Hussain MS, et al. Infarct growth despite successful endovascular reperfusion in acute ischemic stroke: a meta-analysis. *AJNR Am J Neuroradiol*. 2021;42:1472–1478. doi: 10.3174/ajnr.A7177

Stroke
FIRST PROOF ONLY

Downloaded from http://ahajournals.org by on February 11, 2026